“Protect the Pigment”: Alternative to Free Nipple Grafting in Women of Color with Gigantomastia

Jessica R. Cunning, MBA; Arturo J. Rios-Diaz, MD; Olatomide Familusi, MD; Monica Llado-Farrulla, MD; Jesse Y. Hsu, MS PhD; Robyn B. Broach, PhD; Paris D. Butler, MD

Department of Surgery, Division of Plastic Surgery, Hospital of the University of Pennsylvania, Philadelphia, Pennsylvania

BACKGROUND

Breast amputation with free nipple grafting (BA-FNG) is historically recommended for patients with gigantomastia undergoing reduction mammoplasty (RM). However, the resulting nipple-areolar complex (NAC) hypopigmentation is frequent, undesirable, and more apparent in women with more native pigment. Pedicled reductions (PR) provide an opportunity to improve outcomes. We sought to compare NAC aesthetics in a series of non-Caucasian patients by RM technique and to estimate how many patients at a population-based level could potentially benefit from an extended-PR.

METHODS

We identified 15 consecutive patients with gigantomastia (sternal notch-to-nipple distance >40cm) who underwent RM in 2019. NAC aesthetic outcomes of BA-FNG and extended-PR were compared. A patient who underwent a right BA-FNG and left extended-PR served as internal control. The number of RM cases/year and the proportion of BA-FNG procedures in non-Caucasian patients were determined using five statewide inpatient/ambulatory databases. Cancer and reconstructive procedures were excluded.

RESULTS

NAC pigmentation depended on technique (**FIGURE 1**). The BA-FNG patient experienced classic NAC hypopigmentation (**A**). The 14 extended-PR patients experienced no nipple ischemia and retained natural NAC pigment (**B, C**). The internal control demonstrated both NAC outcomes, with the extended-PR producing a better result (**D**). Population-level analyses identified 43,228 RM cases between 2009-2014; 797 patients had concurrent nipple grafts. Overall, 39% of nipple graft patients were women of color. The number of RM cases per year for non-Caucasian patients increased, but nipple graft utilization decreased from 3.1% to 1.8% of cases (**FIGURE 2**).

FIGURE 2. Number of reduction mammoplasty (RM) cases and percentage of RM with nipple grafts among women of color in FL, IA, NE, NY, and UT from 2009-2014

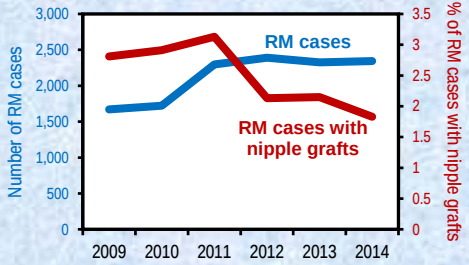

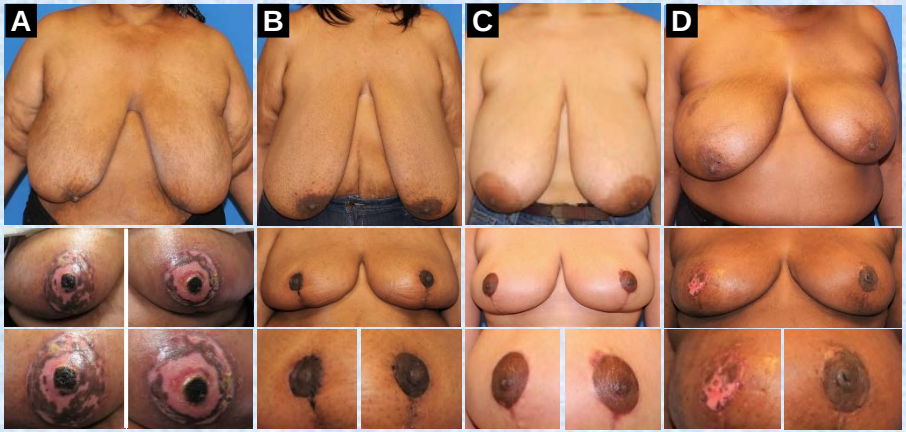

FIGURE 1. Pre- and Postoperative Photos of Patients who Underwent Reduction Mammoplasty **(A)** Patient who underwent BA-FNG. NAC hypopigmentation appreciated at 4 weeks post-op. **(B)** Patient with gigantomastia who underwent PR. NAC retains natural pigmentation 7 weeks post-op. **(C)** Patient with gignatomastia who underwent PR. NAC retains natural pigmentation 3 weeks post-op. **(D)** Patient who underwent a right-sided BA-FNG due to cancer beneath NAC and a left-sided PR– used as internal control. NAC outcomes strikingly different 6 weeks post-op.

DISCUSSION/CONCLUSION

Women of color with gigantomastia undergoing extended-PR have superior NAC aesthetic outcomes, reinforcing that one technique is not suitable for all. Though BA-FNG at a population-level is infrequent relative to the overall number of RM procedures, hundreds of patients’ lives could be improved, suggesting that it is time to revise antiquated treatment guidelines for gigantomastia to adjust for ethnic differences and ensure optimal results for all.